

## ORIGINAL ARTICLE

## EVALUATION OF HEPATOTOXIC AND NEPHROTOXIC EFFECTS OF PIROXICAM SULFONATED DERIVATIVES

Ghazala Shaheen, Asif Ali, Shafiq Ahmad Tariq, Safi Ullah\*, Nuzhat Sultana\*\*, Inayat Shah, Naeem Khan, Syed Muhammad Ashhad Halimi\*, Muhammad Saeed\*, Syed Hamid Habib

Institute of Basic Medical Sciences, Khyber Medical University, \*Department of Pharmacy, University of Peshawar,

\*\*Khyber Medical College, Peshawar, Pakistan

**Background:** Pain management requires new pharmacotherapy with good efficacy and less side effects. Piroxicam is used routinely in clinical practice but it is associated with side effects. To minimize the chances of adverse effects, sulfonated piroxicam derivatives (SPD) have been introduced. We sought to find hepatotoxic and nephrotoxic effects of SPD in Albino rats. **Methods:** An experimental study on SPD was carried out at the Institute of Basic Medical Sciences, Khyber Medical University, Peshawar. Healthy 24 albino rats were divided into 5 groups. One control group and four experimental groups (compound I and II, each with a dose of 10mg/kg and 20mg/kg) received treatment for 7 days. Liver function tests (LFTs), renal function tests (RFTs) and histology of liver and kidney specimens was performed after culling rats. The difference between median values of samples was assessed using Kruskal-Wallis test with post-hoc (for LFTs and RFTs). SPSS-21 was used for all statistical analysis and  $p \leq 0.05$  was considered statistically significant. **Results:** The alanine aminotransferase (ALT) values were significantly high in the 20 mg/Kg group than control for both compounds ( $p=0.03$ ,  $p=0.001$  respectively). The aspartate aminotransferase (AST) values were significantly high in the 10 mg/Kg and 20 mg/Kg group than control for compounds II ( $p=0.01$ ,  $p=0.0001$  respectively). The alkaline phosphatase (ALP) values were significantly high in the 20 mg/Kg group than control for compounds II ( $p=0.002$ ). The blood urea values were significantly high in the 20 mg/Kg group than control for compounds II ( $p=0.008$ ). The mean final score of liver injury in all experimental groups (mean range 5–7) was less suggesting that the damage in liver was less pronounced. Renal injury was more pronounced in the 20 mg/Kg dose for both compound I and compound II (mean score 7) compared to 10 mg/Kg dose (mean score 4). **Conclusion:** Piroxicam sulfonated derivatives can cause focal changes in liver and kidney which might be reversible. The changes are less pronounced for compound I with a low dose.

**Keywords:** Piroxicam, Hepatotoxicity, Nephrotoxicity

Pak J Physiol 2017;13(4):18–22

## INTRODUCTION

It is estimated that worldwide, approximately 20% of adults experience a type of pain, which is broadly classified as acute or chronic.<sup>1</sup> Chronic pain is one of the main reasons that people seek medical care. It leads to personal suffering and it also has adverse effect on individual productivity at work place.<sup>2</sup> Pain management requires new pharmacotherapy with good efficacy and less side effects. At present, pharmacotherapy for pain management mainly includes non-steroidal anti-inflammatory drugs (NSAIDs) and narcotic analgesics.<sup>3</sup> Patients expect at least 50% reduction in the intensity of pain without risk of experiencing adverse effects.<sup>4</sup> Non-steroidal anti-inflammatory drugs are preferred by practitioners because they are in clinical use since long with good efficacy and low drug abuse potential.<sup>5</sup>

Piroxicam is a type of NSAID with low solubility and high permeability. It is widely used as an analgesic and anti-inflammatory agent in clinical practice. Piroxicam is preferred for the treatment of pain associated with rheumatoid arthritis and osteoarthritis

than other drugs due to its long half-life (40 hrs), which makes once a day dosage possible. It is also used in musculoskeletal disease, dysmenorrhea, postoperative pain and rheumatic disease.<sup>6</sup>

However, like other NSAIDs, the use of piroxicam is associated with side effects including gastrointestinal<sup>7</sup>, cerebrovascular<sup>8</sup>, hypersensitivity<sup>9</sup>, respiratory<sup>10</sup>, bone related<sup>11</sup>, hepatotoxicity<sup>12</sup> and nephrotoxicity.<sup>13</sup>

Thus, the benefit of NSAIDs could further be improved through controlling the adverse effects. This will clearly have a large market potential. Withdrawal of drugs from market can occur because of two main causes i.e. renal and hepatic adverse events. Serum biochemistry measurements and histopathology tests can be used to evaluate hepatic and renal damage in pre-clinical animal models.<sup>14</sup>

To minimize the chances of adverse effects, sulfonated piroxicam derivatives have been introduced. The anti-nociceptive activity of sulfonated piroxicam derivatives has been evaluated in rat model and it has been found to have significant peripheral pain relieving effect.<sup>15</sup> Thus, we conducted the current study to find

hepatotoxic and nephrotoxic effects of piroxicam sulfonated derivatives in Albino rats.

## MATERIAL AND METHODS

It was a non-randomized control trial carried out at the Institute of Basic Medical Sciences (IBMS) Khyber Medical University (KMU), Peshawar after getting permission from Institutional Review Board of the university. The piroxicam derivatives used in the current study were as follows:

**Compound I:** (white colour) '2-methyl-1,1-dioxo-3-[(pyridin-2-ylamino) carbonyl]-1,2-dihydro-1H<sup>6</sup>,2-benzothiazin-4-yl 2,4-dichlorobenzenesulfonate'.

**Compound II:** (yellow colour) '2-methyl-1,1-dioxo-3-[(pyridin-2-ylamino) carbonyl]-1,2,3,8a-tetrahydro-1H<sup>6</sup>,2-benzothiazin-4-yl 4-chlorobenzenesulfonate'. Both compounds were synthesized and provided by Department of Pharmacy, University of Peshawar.

Healthy 24 albino rats weighing 150 to 250 grams were purchased from rat house facility of Peshawar Medical College, Peshawar. Diseased and pregnant rats were not included in our study. In all experiments, test rats were treated according to ethical procedures approved by the ethical committee. They were kept in animal house facility at the Department of Pharmacology, IBMS, KMU. After one week of acclimatization, rats were divided into 5 groups randomly. There were one control group and four experimental groups. Through intra-peritoneal route, normal saline (10 ml/Kg) was injected to control group (group I) and sulfonated derivatives of piroxicam [group II (test compound I, 10 mg/Kg), group III (test compound I, 20 mg/Kg), group IV (test compound 2, 10 mg/Kg) and group V (test compound 2, 20 mg/Kg)] were injected to rats in experimental groups. These experimental rats were given treatment for 7 days. After 7 days, respective rats were anaesthetized with injection sodium thiopental and sacrificed through cervical dislocation. The blood samples were obtained through cardiac puncture in disposable syringes for liver function tests (LFTs) and renal function tests (RFTs). The normal ranges of LFTs and RFTs in rats were used as a reference.<sup>16</sup> The liver and kidney specimens were grossly examined, fixed in formalin and processed into paraffin embedded tissue blocks. Sections of 4 µm were cut and stained for hematoxylin and eosin for histopathological evaluation using standard criteria used by Gokakin *et al*<sup>17</sup>. The difference between median values of samples was assessed using Kruskal-Wallis test followed by post-hoc analysis. The post-hoc approach used was pairwise Mann-Whitney U-tests. Adjustment for the *p*-values was made through a *p adjusted method* to prevent type 1 error rates. SPSS-21 was used for statistical analysis and *p*≤0.05 was considered statistically significant.

## RESULTS

Analyses of biochemical parameters (LFTs and RFTs) after the use of experimental compound I and II is shown in Table-1. In LFTs, a statistically significant difference between the median values of groups was observed for alanine aminotransferase (ALT) (normal range, 17.5–30.2 IU/L) (*p*=0.001). In pairwise comparison the difference between the control vs group III (*p*=0.03) and control vs group V (*p*=0.001) was statistically significant. In addition, a statistically significant difference between the median values of groups was observed for aspartate aminotransferase (AST) values (normal range 45.7–80.8 IU/L) (*p*=0.0001). In pairwise comparison the difference between the control vs group IV (*p*=0.01) and control vs group V (*p*=0.0001) was statistically significant. Furthermore, a statistically significant difference between the median values of groups was observed for alkaline phosphatase (ALP) values (normal range 56.8–128 IU/L) (*p*=0.001). In pairwise comparison the difference between the control vs group V (*p*=0.002) was statistically significant. For total serum bilirubin (TSB) (normal range 0.2–0.55 mg/dL), no statistically significant difference was observed (*p*=0.16).

In RFTs, a statistically significant difference between the median values of groups was observed for blood urea values (normal range 15–21 mg/dl) (*p*=0.002). In pairwise comparison the difference between the control vs group V (*p*=0.008) was statistically significant. Finally, for serum creatinine (normal range 0.2–0.8 mg/dl), no statistically significant difference was observed (*p*=0.25) (Table-1).

**Table-1: Comparison of median values of study variables across the groups after 7 days of treatment**

Groups	LFTs (median)				RFTs (median)	
	ALT (IU/L)	AST (IU/L)	ALP (IU/L)	TSB (mg/dl)	Urea (mg/dl)	Creatinine (mg/dl)
Control	32.5	198	212	0.4	30	0.6
Group I	39	245	254	0.4	30	0.5
Group II	44	277	258	0.5	38	0.5
Group III	38	424	246	0.4	35	0.7
Group IV	48	482	266	0.4	44	0.7
<i>p</i> value	0.001*	0.001*	0.001*	0.16	0.002*	0.25

\**p*<0.05

The histopathologic scoring for assessing liver and kidney injury are shown in Table 2 and Table 3. The control group was without any liver and kidney injury. However, focal areas of injury were noted in both liver and kidney specimens with both the compounds (Table-2 and 3).

Liver injury was assessed based on hyperemia, cloudy swelling of hepatocyte, vacuolar degeneration, mononuclear cell infiltrations, necrosis in 1–3 hepatocytes, necrosis in more than 3 hepatocyte and hemorrhage. The mean final score of liver injury in all

experimental groups (range 5–7) was less suggesting that the damage in liver was less pronounced (Table-2, Figure-1).

A similar pattern of overall less pronounced injury was observed in kidney specimens with total mean score of renal injury in a range of 4–7. However,

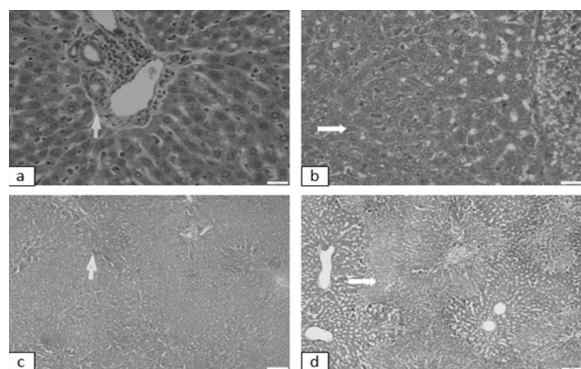
renal injury was more pronounced in the 20 mg/Kg dose for both compound I and compound II (total mean renal injury score 7 for both) compared to 10 mg/Kg dose (total mean renal injury score 4 for both) (Table-3, Figure-2).

**Table-2: Mean histopathological scoring of hepatic injury after 7 days of treatment in experimental rats**

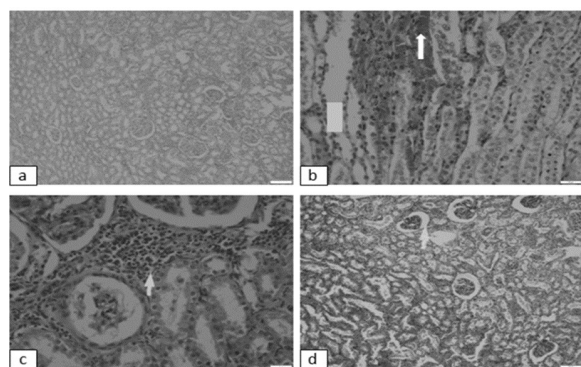
Groups	Hyperemia	Cloudy swelling of hepatocyte	Vacuolar degeneration	Mononuclear cell infiltrations	Necrosis in 1–3 hepatocytes	Necrosis in >3 hepatocytes	Haemorrhage	Total Mean Score (14)
Group I	0	0	0	0	0	0	0	0
Group II	1	0	1	0	0	0	3	5
Group III	1	0	2	0	1	1.5	1.5	7
Group IV	1	1	1	0	0	0	3	6
Group V	1	0	0	0	0	2	3	6

**Table-3: Mean histopathological scoring of renal injury after 7 days of treatment in experimental rats**

Groups	Hyperemia	Glomerular space expansion	Glomerular mesangial cell hyperplasia	Tubular epithelial degeneration	Mononuclear cell infiltrations	Tubular epithelial necrosis	Haemorrhage	Total Mean Score (14)
Group I	0	0	0	0	0	0	0	0
Group II	0	0.5	1	0	1	0	1.5	4
Group III	0.5	0.5	2	0	1	0	3	7
Group IV	0.5	0.5	0	0	0	0	3	4
Group V	1	1	2	0	0	0	3	7



**Figure-1: Histopathological changes in liver after 7 days of treatment. a) control group (white arrow) in control group. White arrows showing focal haemorrhage (b) and necrosis (c & d)**



**Figure-2: Histopathological changes in kidneys after 7 days of treatment. a) control group, white arrows showing hyperemia (b) interstitial inflammation (c) and glomerular space expansion (d)**

## DISCUSSION

In the current study, two sulfonated piroxicam derivative compounds (I and II) were tested for their effect on liver and kidney histology and biochemical changes in LFTs and RFTs. Overall, both liver and renal damage were observed in histology, which was reflected in changes in biochemistry of rats, i.e., elevated LFTs and RFTs. Although, neither the hepatic, nor the renal injury was lethal to rats, compound II was found more toxic and compound I with 10 mg/Kg was least toxic.

Small molecules in relation to biological systems are studied by chemical biologists. The concept of BIOS (biology oriented synthesis) is the beginning of the exploration of advanced medicine. It is the art of creation and collection of compounds.<sup>18</sup> Piroxicam is included in oxicam class of drugs on the basis of chemical classification.<sup>19</sup> Piroxicam is routinely used as a pain-killer in medicine. Piroxicam sulfonated derivatives have been synthesized by BIODS (biology oriented drug synthesis). These derivatives were found safe and effective analgesics.<sup>15</sup> We designed the current study to assess the hepatic and renal toxicity profile of newly synthesized sulfonated derivatives of piroxicam.

The major organ responsible for secretion of clotting factors, enzymes involved in drug metabolism and excretion of waste products from the body is liver. Liver damage occur by drugs, cholesterol overload, alcohol intake, bile duct obstruction and viruses.<sup>20</sup> ALT, AST, ALP and TSB are released into blood after hepatocytes are damaged.<sup>21,22</sup> Reactive oxygen species (ROS) are normally generated by liver cells because of their ability to actively involve in various metabolic

functions. After administration of drugs, ROS can be excessively generated and antioxidant reserves are depleted. ROS can cause nucleic acid damage, sulfhydryl antioxidants inactivation, initiation of lipid peroxidation of cell membrane and inhibition of DNA repair in liver cells. Hepatotoxicity can be assessed quantitatively by measuring serum levels of AST, ALT, ALP and TSB, as these are markers of hepatic damage. Normal values of these enzymes are different in rats<sup>16</sup> than in humans but their rise above normal range show hepatic damage.<sup>23</sup> Drug induced hepatic damage is one of the most common cause of withdrawal of drug from market in spite of careful preclinical and clinical studies. In the current study, all the hepatic markers were elevated after the use of piroxicam derivatives. The rise in the levels of hepatic markers displayed dose dependant response for both compound I and compound II. In addition, AST values were significantly higher for compound II (both doses) than control pointing towards a more hepatotoxic effect. These findings thus show that compound I with 10 mg/Kg dose might be a better option with less chances of toxicity.

Furthermore, cytoplasmic vacuolation is one of the first responses of cell to all types of injuries.<sup>17</sup> Thus, vacuolar degeneration and other parameters were assessed histologically in tissue specimens. Focal hepatic damage was observed after the use of piroxicam derivatives for compound I and II. However, even after partial hepatectomy, liver cell of rats are regenerated after two weeks.<sup>24</sup> Thus, we presume that the hepatic damage in the current study could potentially be recovered after discontinuation of piroxicam derivatives.

Drug administration can result in increased levels of blood urea and serum creatinine.<sup>25</sup> In the current study, blood urea levels were significantly increased for compound II with 20 mg/Kg dose pointing towards a potential renal damage. This result was reflected histologically and renal damage was observed with hyperemia, glomerular space expansion, mesangial cell proliferation and focal haemorrhage. However, again renal damage was focal and less pronounced for lower dose. Kidney tubules have great capacity to regenerate damage cell within a week.<sup>26</sup> Thus, we presume that renal damage in the current study especially for lower doses of both compounds could be recovered after discontinuation of piroxicam derivatives. The study is limited by a relatively small sample size and the lack of inclusion of a positive control group with higher doses of piroxicam derivatives

## CONCLUSION

Piroxicam sulfonated derivatives can cause focal changes in liver and kidney which might be reversible. The changes are less pronounced for compound I with 10 mg/Kg dose. In addition, these piroxicam sulfonated derivatives could potentially be used as analgesic with

prior exclusion of hepatic and renal impairment in further pre-clinical studies and phase I clinical trials.

## REFERENCES

- Lumley MA, Cohen JL, Borszcz GS, Cano A, Radcliffe AM, Porter LS, *et al.* Pain and emotion: a biopsychosocial review of recent research. *J Clin Psychol* 2011;67(9):942–68.
- Veehof MM, Oskam M-J, Schreurs KM, Bohlmeijer ET. Acceptance-based interventions for the treatment of chronic pain: a systematic review and meta-analysis. *Pain* 2011;152(3):533–42.
- Borsook D, Hargreaves R, Bountra C, Porreca F. Lost but making progress—Where will new analgesic drugs come from? *Sci Transl Med* 2014;6(249):249sr3–sr3.
- Moore A, Derry S, Eccleston C, Kalso E. Expect analgesic failure; pursue analgesic success. *BMJ* 2013;346.
- Brune K, Patrignani P. New insights into the use of currently available non-steroidal anti-inflammatory drugs. *J Pain Res* 2015;8:105.
- Trivedi M. Spectroscopic characterization of disulfiram and nicotinic acid after biofield treatment. *J Anal Bioanal Tech* 2015;6:265.
- Laine L. NSAID-associated gastrointestinal bleeding: assessing the role of concomitant medications. *Gastroenterology* 2014;147(4):730–3.
- Roubille C, Martel-Pelletier J, Davy J-M, Haraoui B, Pelletier J-P. Cardiovascular adverse effects of anti-inflammatory drugs. *Antiinflamm Antiallergy Agents Med Chem* 2013;12(1):55–67.
- Kowalski ML, Makowska J, Blanca M, Bavbek S, Bochenek G, Bousquet J, *et al.* Hypersensitivity to nonsteroidal anti-inflammatory drugs (NSAIDs)—classification, diagnosis and management: review of the EAACI/ENDA and GA2LEN/HANNA. *Allergy* 2011;66(7):818–29.
- Buer JK. Origins and impact of the term ‘NSAID’. *Inflammopharmacology* 2014;22(5):263–7.
- van Esch RW, Kool MM, van As S. NSAIDs can have adverse effects on bone healing. *Med Hypotheses* 2013;81(2):343–6.
- Ilic S, Drmic D, Franjic S, Kolenc D, Coric M, Brcic L, *et al.* Pentadecapeptide BPC 157 and its effects on a NSAID toxicity model: diclofenac-induced gastrointestinal, liver, and encephalopathy lesions. *Life Sci* 2011;88(11):535–42.
- Möller B, Pruijm M, Adler S, Scherer A, Villiger PM, Finckh A. Chronic NSAID use and long-term decline of renal function in a prospective rheumatoid arthritis cohort study. *Ann Rheum Dis* 2015;74(4):718–23.
- Jiang Y, Gu L, Zhang R, Zhang Y, Zhang L, Ju P, *et al.* Evaluation of the indicative roles of seven potential biomarkers on hepato-nephrotoxicity induced by Genkwa Flos. *J Ethnopharmacol* 2014;158:317–24.
- Ullah S, Saeed M, Halimi SMA, Fakhri MI, Khan KM, Khan I, *et al.* Piroxicam sulfonates biology-oriented drug synthesis (BIODS), characterization and anti-nociceptive screening. *Med Chem Res* 2016;25(7):1468–75.
- Mehren KG. Exotic Companion Medicine Handbook for Veterinarians. *Can Vet J* 1999;40(4):275–6.
- Gökakın AK, Atabey M, Deveci K, Sancakdar E, Tuzcu M, Duger C, *et al.* The effects of sildenafil in liver and kidney injury in a rat model of severe scald burn: a biochemical and histopathological study. *Ulus Travma Acil Cerrahi Derg* 2014;20(5):319–27.
- Wilk W, Zimmermann TJ, Kaiser M, Waldmann H. Principles, implementation, and application of biology-oriented synthesis (BIOS). *Biol Chem* 2010;391(5):491–7.
- Manohara C, Sanganal S, Prem K, Swamy K, Phani A. Improved dissolution rate of Piroxicam by fusion solid dispersion technique. *Sci Tech Arts Res J* 2014;3(1):44–7.
- Yadav N, Dixit V. Hepatoprotective activity of leaves of *Kalanchoe pinnata* Pers. *J Ethnopharmacol* 2003;86(2):197–202.
- Sureshkumar S, Mishra S. PHCOG MAG. Research Article Hepatoprotective activity of extracts from *Pergularia daemia*

- Forsk against carbon tetrachloride-induced toxicity in rats. *Phcog Mag* 2007;3(11):187.
22. Eidi A, Mortazavi P, Bazargan M, Zaringhalam J. Hepatoprotective activity of cinnamon ethanolic extract against CCl<sub>4</sub>-induced liver injury in rats. *Excli J* 2012;11:495.
  23. Farooq Y, Khan MA, Farooq MA. Liver function tests, red cell indices and oxidative stress in healthy male Sprague Dawley rats. *Pak J Physiol* 2015;11(3):10–3.
  24. Mossalam HH, yhtaF Yousuf A. Hepatotoxic potential of leflunomide drug in adult male albino rats. *AAMJ* 2013;11:284–309.
  25. Mershiba SD, Dassprakash MV, Saraswathy SD. Protective effect of naringenin on hepatic and renal dysfunction and oxidative stress in arsenic intoxicated rats. *Mol Biol Rep* 2013;40(5):3681–91.
  26. Berger K, Moeller MJ, editors. Mechanisms of epithelial repair and regeneration after acute kidney injury. *Semin Nephrol* 2014;34(4):394–403.
- 

**Address for Correspondence:**

**Dr Asif Ali**, Assistant Professor of Pathology, Institute of Basic Medical Sciences, Khyber Medical University, Peshawar, Pakistan. **Cell:** +92-333-9929282

**Email:** draliasif7@gmail.com; Asif.Ali@Glasgow.ac.uk

Received: 17 Aug 2017

Reviewed: 6 Oct 2017

Accepted: 6 Oct 2017