

## ORIGINAL ARTICLE

## INTEGRIN BETA2 GENE VARIANT CAUSING LEUKOCYTE ADHESION DEFICIENCY TYPE 1 IN A PAKISTANI FAMILY

Rabea Nasir, Sheeba Shabbir\*, Lubna Siddique\*\*, Shahida Awais\*\*\*, Zara Khalid†, Ambreen Zahoor††, Zahid Azeem†††, Farzana Majeed‡

Department of Physiology, M. Islam Medical College Gujranwala, \*Department of Forensic Sciences, HBS Medical & Dental College, \*\*Department of Physiology, Rawal Institute of Health Sciences, \*\*\*Fazaia Medical College, †Department of Biochemistry, Rawal Institute of Health Sciences, ††Department of Medicine, HBS Medical & Dental College, Islamabad, †††Department of Biochemistry, AJK Medical College, Muzaffarabad, ‡Department of Physiology, HBS Medical & Dental College, Islamabad, Pakistan

**Background:** Leukocyte adhesion deficiency type 1 (LAD1), an autosomal recessive condition, arises from partial or complete deficiency of CD18 expression. LAD1 patients commonly manifest recurrent skin and respiratory tract infections, delayed umbilical cord separation, and impaired wound healing due to hindered leukocyte migration. This study aims to clinically and molecularly diagnose LAD in a highly consanguineous Pakistani family, investigating a recurrent mutation within the integrin  $\beta 2$  (*ITGB2*) gene. **Methods:** A comprehensive clinical and molecular diagnosis of LAD1 was made in on a patient from a consanguineous Pakistani family. Lymphocyte subset analysis was performed using a flow cytometer, followed by whole exome sequencing and DNA Sanger sequencing to identify the pathogenic mutation within the *ITGB2* gene. Further to provide genetic counselling all the healthy siblings were also Sanger sequenced. **Results:** Flow cytometry indicated CD18 deficiency, while sequencing of the *ITGB2* gene unveiled a nonsense mutation, c.186C>A, p. (Cys62\*), located in exon four. This mutation segregates in an autosomal recessive pattern within the family. **Conclusion:** A mutation c.186C>A (Cys62\*) in a patient of LAD1 was identified which is potentially pathogenic in nature.

**Keywords:** Genetic study, Whole exome sequencing, Sanger sequencing, Flow cytometry, Leukocyte adhesion deficiency

Pak J Physiol 2024;20(1):15–8

## INTRODUCTION

Leukocyte adhesion deficiency type 1 (LAD1; OMIM #116920) is a rare (1 in 100,000 live births) autosomal recessive type of inherited disorder. Common manifestations include repeated bacterial and fungal infections including skin and respiratory tract infections, delayed wound healing, skin ulcers, and sepsis and otitis media owing to the barrier of leukocyte migration to the site of infection.<sup>1</sup> The hallmark features include delayed separation of the umbilical cord and elevated white blood cells (leukocytosis).<sup>1-3</sup>

The first case of LAD1 was reported back in 1980 and till now more than 300 patients have been reported worldwide.<sup>3</sup> More than 26 cases have been reported only from Pakistan. Over 80 homozygous mutations in Integrin  $\beta 2$  (*ITGB2*) gene have been reported producing a variety of different LAD1 phenotypes including severe (<2% expression of  $\beta 2$  integrins) or moderate (2–30% expression of  $\beta 2$  integrins).<sup>4</sup> Mutations in the gene *ITGB2* (OMIM, 116920) have been reported to cause LAD1. The gene is localized on 21q22.3 comprising 16 exons, which encode 769 amino acids (approximately 85–95 KD)  $\beta 2$  integrin protein (CD18).<sup>5,6</sup> The protein CD18 on the surface of leukocytes is involved in adhesion and transmigration. Patients with impaired functional CD18 suffer from LAD1, where accumulation of myeloid leukocytes is observed at extravascular sites. Therefore

elevated levels of leukocytes, neutrophils, and recurrent infections are observed due to the inability to recruit leukocytes at the site of infections.<sup>7-9</sup>

Disease diagnosis is based on analysis of CD18 expression on the surface of leukocytes using flow cytometry.<sup>7,10</sup> Based on the CD18 expression disease can be grouped into moderate with 2–30% and severe with <2%. Patients suffering from moderate levels of CD18 expression survive early childhood with proper antibiotics while patients suffering from a severe type of LAD1 succumbed to infections.<sup>3</sup>

Early diagnosis should be considered in every patient with recurrent infection and a markedly increased leukocyte count. Physicians should opt for flow-cytometry for an early diagnosis in patients with repeated infections, marked leukocytosis, and delayed umbilical cord separation. To find the exact defect at the molecular level *ITGB2* gene is Sanger Sequenced.<sup>3,11</sup> A molecular diagnosis approach including Sanger sequencing is highly recommended to define the precise molecular defect in the  $\beta 2$  subunit.<sup>3,12</sup>

According to (Medline plus.gov and Human Genome Mutation Data Bank, HGMD) at least 90 different *ITGB2* gene mutations have been identified causing LAD1.<sup>13</sup> The mutations include missense, nonsense, splice site, and deletion mutations. The majority of these mutations fall in exons 5 to 9 that encode the  $\beta 1$  domain of *ITGB2*. The present study reveals a clinical and molecular diagnosis of LAD1 in a

6-month-old male from a highly consanguine Pakistani family. DNA Sanger sequencing identified a nonsense mutation (p.Cys62\*).

## METHODOLOGY

In this project, we enrolled a 6-month-old boy suffering from LAD1, born to a highly consanguine family from a remote area of Punjab, Pakistan. The patient was admitted to Aga Khan University Hospital, Karachi, Pakistan. The patient was thoroughly examined for infections such as gastrointestinal tract (diarrhoea) skin (omphalitis) and respiratory tract (sinusitis, tonsillitis, otitis media, pharyngitis, and pneumonia) by an expert team of paediatricians in the Department of Paediatrics, Aga Khan University Hospital.

Flow cytometry was performed to check the status of the lymphocyte subset in patients at the Armed Forces Institute of Pathology, Department of Immunology (AFIP-Immunology), Rawalpindi. Under the supervision of an expert immunologist detailed clinical history was collected for immune deficiency workup. The genetic analysis including, polymerase chain reaction and DNA sequencing, was carried out at the Biological Sciences Department, Quaid-i-Azam University, Islamabad, Pakistan. To have permission to publish the research findings written signed consent was obtained from parents. Study approval was granted by the Institutional Review Board of HBS Medical and Dental College, Islamabad.

Based on clinical history patient was suspected of having LAD1. To perform immunological (flow cytometry) and haematological test (blood complete picture) studies whole blood samples of approximately 5 mL were drawn into EDTA tubes. Flow cytometry and blood complete picture were performed on an automated Sysmex KX21 Hematology Analyzer (Sysmex Corporation, Japan). Lymphocyte subset analysis was performed on a FACScanto II machine (Becton Dickinson, USA) using CF11bPE, CD18FITC, and anti-CD11C antibodies. Processed patient samples by the addition of required RBC lysis (stain/lyse/wash procedure) proper washing with recommended antibodies and were taken to flow cytometer and analysed using BD software of FACSDiva. LAD1 classification CD18 concentration as (moderate >2%) and severe (<2%) were applied to the patient's sample.<sup>3</sup> European Society for Immunodeficiencies (ESID) probable criteria were used for establishing LAD1.<sup>10</sup>

To perform genetic analysis whole blood samples (3–5 mL) were collected from the patient, parents, and available healthy siblings. Using QIAamp<sup>®</sup> DNA Mini Kit (Hilden Germany), DNA was extracted from available blood and was quantified on a Nanodrop1000 spectrophotometer (Thermal Scientific, Wilmington, MA, USA). Using Primer-3 software

(<http://bioinfo.ut.ee/primer3-0.4.0/>) *ITGB2* gene exon-specific primers were constructed. Using standard PCR protocol<sup>14</sup> each *ITGB2* protein-coding exons was PCR amplified. The qualitative analysis of PCR amplified products (3  $\mu$ L) was performed by ethidium bromide-stained 2% agarose gel electrophoresis under a UV illuminator. Later, PCR-amplified products were purified using a commercially available kit (Axygen, CA, USA). Purified PCR products were subjected to Sanger Sequencing using BigDye Terminator v-3.1 Cycle Sequencing Kit on Beckman Coulter CEQ-8000 Analyzer (Stanwood, Washington, USA).

DNA Sanger sequencing files for each exon of the *ITGB2* gene were analysed by comparing them with corresponding control gene sequences obtained from the Ensemble Genome Browser database (<http://ensembl.org/index.html>). To nucleotide sequence variant BioEdit sequence alignment editor version 6.0.7 was used. The pathogenicity score of the identified variants was measured using MutationTaster (<http://www.mutationtaster.org/>), and Polymorphism Phenotyping V2 (PolyPhen 2).

## RESULTS

The patient enrolled in the current study belonged to a highly consanguine family from Punjab (Figure-1A). On admission, the patient was anaemic with a fever of 39 °C. Detailed clinical examination by the expert team of physicians revealed that the patient was suffering from respiratory tract and skin infections. There had been a delay in umbilical cord separation for more than two weeks. The detachment site of the umbilical cord and site of skin infection was devoid of pus formation (Table-1). At the age of 2 months abscess developed behind the left ear which was drained two times along with on-and-off fever and vomiting. Skin abscess behind left ear was observed at the age of 2 months which was drained two times. The patient had on and off fever with vomiting. Ultrasound revealed no sign of lymphadenopathy or hepatosplenomegaly. Other examinations including cardiovascular and nervous systems remained unremarkable.

Figure-1A shows pedigree of the family suffering from LAD1. Circles show females while squares show males. Double lines between I-1 and I-2 show consanguine marriage. Filled circle (II-3) shows patient. Figure-1B shows a chromatogram obtained through Sanger sequencing. Arrowhead showing the position of *ITGB2* exons 5 mutation [c.186C>A, p.(Cys62\*)] in the patient (II-1), carrier (Father I-2), and healthy sibling (II-3).

The LAD1 diagnosis was done through clinical tests such as immune functions and flow cytometer. The patient's immunoglobulin levels (IgG, IgM, and IgA) are shown in Table-1. Blood complete picture test revealed leukocytosis compared to relative

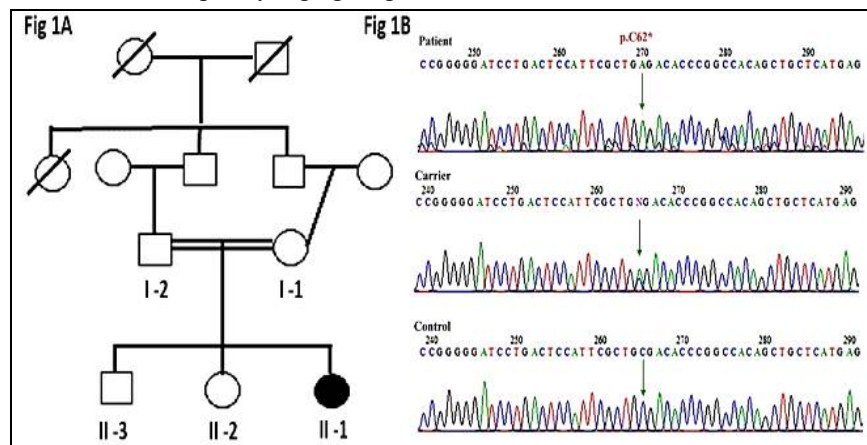
neutrophilia. Blood complete picture test revealed white blood cell ( $11.7 \times 10^3/L$ ), platelets count ( $338 \times 10^9/L$ ), lymphocyte (13.5%), neutrophils (84.7%), and CRP (56.60 mg/dL). Similarly, lymphocyte subset analysis revealed raised T, B and NK cells (Table-1). Flow-cytometry based Dihydro rhodamine (DHR) assay and nitroblue tetrazolium slide test (NBT) were negative for neutrophil function. Flow cytometry was performed which clearly showed a reduced level of CD18 expression (Figure-2). These findings were consistent with leukocyte adhesion deficiency type I (LAD1) disease.

Whole exome sequencing (WES) identified two homozygous variants in genes (*NCF2*) on chromosome 1 and *ITGB2* on chromosome 21. Besides homozygous mutations, heterozygous variants in 5 other genes were also identified (Figure-1). Based on laboratory findings which were consistent with LAD1 deficiency the underlying disease-causing gene *ITGB2* was completely Sanger sequenced which revealed a non-sense mutation [c.186C>A, p.(Cys62\*)]. This non-sense mutation was found to be completely segregating

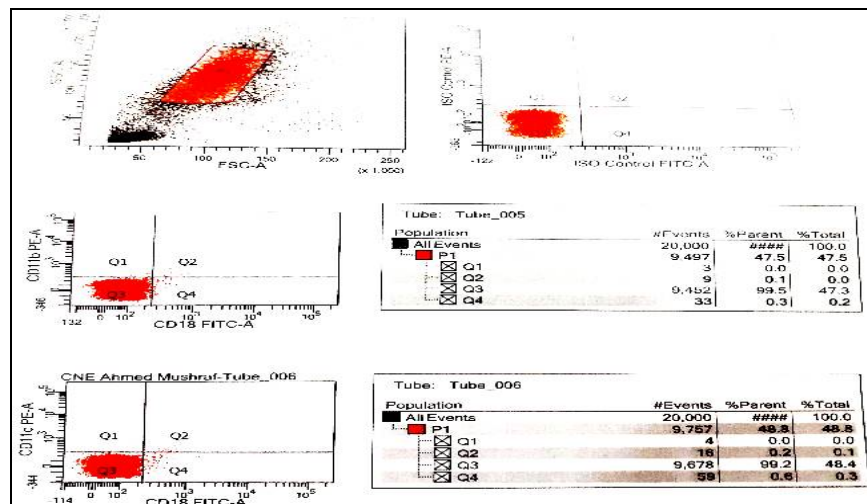
in the family including parents as (heterozygous) and healthy siblings (Figure-1).

**Table-1: Patient blood complete picture and immunological tests**

Name of Test	Patient value	Reference Value
<b>Total Leucocyte Count</b>	$16.7 \times 10^3$ cells/ $\mu$ L	$4-15 \times 10^3$ cells/ $\mu$ L
<b>Haemoglobin level</b>	12.7 g/dL	11.1-16.3 g/dL
<b>Lymphocytes</b>	13.5% ( $12.1 \times 10^3/\mu$ L)	20-40% ( $1-3 \times 10^3$ cells/ $\mu$ L)
<b>Neutrophils</b>	83.7% ( $97.5 \times 10^3/\mu$ L)	40-80% ( $2-7 \times 10^3$ cells/ $\mu$ L)
<b>Platelets</b>	$273 \times 10^3/\mu$ L	$150-410 \times 10^3$ cells/ $\mu$ L
<b>Monocytes</b>	7% ( $8.3 \times 10^3/\mu$ L)	2-10% ( $0.2-1 \times 10^3$ cells/ $\mu$ L)
<b>Immunological Work-up</b>		<b>Reference range</b>
<b>Serum Immunoglobulins (Ig)</b>		
IgG	8.5	2.3-14.1 g/L
IgA	0.19	0-0.83 g/L
IgM	1.10	0-1.45 g/L
IgE	165	<100 IU/mL
<b>Neutrophil Function test</b>		
NBT <sup>1</sup> slide test	No abnormality detected	
Dihydrorhodamine Test	Stimulation Index (SI)=400 (Control=200)	
C-Reactive Protein	56.6 mg/dL	0.9 mg/dL
Flow cytometric analysis	Expression of CD11b, CD11c, and CD18 was less than 1% on the patient's neutrophils	
C-reactive Protein-H	35 mg/dL	<0.744 mg/dL



**Figure-1: Pedigree and *ITGB2* Sequencing**



**Figure-2: Flow cytometric analysis**

The photograph is showing absence of (<1%) CD11b, CD11c and Cd18 on granulocytes

## DISCUSSION

LAD1 is the most common leukocyte adhesion deficiency and mutations in the Integrin Subunit Beta-2 gene (*ITGB2*) have been reported causing LAD1 in more than 300 cases worldwide. Leukocyte adhesion deficiency is characterized by recurrent skin and respiratory tract infection with delayed umbilical cord separation.<sup>1-3</sup>

LAD1-specific diagnosis was established by deficiency of integrin subunit of  $\beta$ -2 (CD18) expression on the leukocyte surface. Based on the concentration of CD18 expression in leukocytes, the severity of the LAD1 disease can be established.<sup>3</sup> LAD1 patient's blood complete picture test presents leukocytosis and neutrophilia. CD18 molecules allow neutrophils to move out of the bloodstream to migrate to the site of infection. Those with partial reduction in CD18 expression exhibit less severe symptoms and can survive till adulthood.<sup>6</sup>

In the present study, we enrolled a 6-month-old male patient from remote village of Punjab, Pakistan. The patient succumbed to repeated respiratory tract infections and delayed (more than 2 weeks) umbilical cord separation and expired in 8<sup>th</sup> month soon after initial diagnosis. These clinical manifestations were coherent with earlier studies in other populations.<sup>3,4,15</sup>

Flow cytometry in the case presented in the current study revealed (<2% CD18) molecules, whole exome sequencing identified previously reported nonsense mutation [p. (Cys62\*)] and its segregation in the Tri-ADD was confirmed through Sanger sequencing.<sup>14</sup> This non-sense mutation is located at the tightly folded N-terminal extracellular domain of the integrin  $\beta$ 2 subunit. This  $\beta$ 2 integrin extracellular domain is involved in communication between  $\alpha$  and  $\beta$  subunits.<sup>3,16</sup>

This study presents detailed clinical features in patients suffering from LAD1 from a consanguine family. Flow cytometry revealed the severe type of leukocyte adhesion deficiency while WES identified a non-sense mutation in the *ITGB2* gene. The clinical and laboratory findings are compatible with those reported earlier. This study will not only help in screening patients with recurrent skin infections and neutrophilia for LAD1 disorder but will also facilitate genetic counselling in the Pakistani population.

## Address for Correspondence:

**Prof Dr Farzana Majeed**, Department of Physiology, HBS Medical & Dental College, Shaheed Zulfiqar Ali Bhutto Medical University, Islamabad, Pakistan. **Cell:** +92-334-5597265  
**Email:** drfarzanajaved@hotmail.com

Received: 12 Dec 2023

Reviewed: 15 Jan 2024

Accepted: 25 Jan 2024

## Contribution of Authors:

**RN:** Manuscript writing, data analysis  
**SS:** Laboratory data acquisition and analysis  
**LS:** Data formatting interpretation  
**SA:** Literature Review and data analysis

**ZK:** Laboratory work and data analysis  
**AZ:** Data acquisition and literature search  
**ZA:** Critical review and final approval for submission  
**FM:** Manuscript review, and Approval

**Conflict of Interest:** None      **Funding:** None

## REFERENCES

1. Ganesh A, Al-Zuhaibi SS, Bialasiewicz AA, Al-Abri R, Ahmed S, Al-Tamemi S, *et al.* Necrotizing Pseudomonas infection of the ocular adnexa in an infant with leukocyte adhesion defect. *J Pediatr Ophthalmol Strabismus* 2007;44(4):199-200.
2. Bousfiha A, Jeddane L, Picard C, Al-Herz W, Ailal F, Chatila T, *et al.* Human inborn errors of immunity: 2019 update of the IUIS phenotypical classification. *Journal of Clin Immunol* 2020;40(1):66-81.
3. Kambli PM, Bargir UA, Yadav RM, Gupta MR, Dalvi AD, Hule G, *et al.* Clinical and genetic spectrum of a large cohort of patients with leukocyte adhesion deficiency type 1 and 3: a multicentric study from India. *Front Immunol* 2020 Dec 16;11:612703.
4. Bashir MM, Hussain M, Ahmad D, Tipu HN. Leukocyte adhesion deficiency type 1 with low expression of CD 11b. *J Coll Physicians Surg Pak* 2018;28(6):S87-8.
5. Cox DP, Weathers DR. Leukocyte adhesion deficiency type 1: an important consideration in the clinical differential diagnosis of prepubertal periodontitis. A case report and review of the literature. *Oral Surg Oral Med Oral Pathol Oral Radiol Endod* 2008;105(1):86-90.
6. Bednarczyk M, Stege H, Grabbe S, Bros M.  $\beta$ 2 Integrins—multi-functional leukocyte receptors in health and disease. *Int J Mol Sci* 2020;21(4):1402.
7. Anderson DC, Springer TA. Leukocyte adhesion deficiency: an inherited defect in the Mac-1, LFA-1, and p150, 95 glycoproteins. *Annu Rev Med* 1987;38(1):175-94.
8. Solomon E, Palmer RW, Hing S, Law SK. Regional localization of CD18, the  $\beta$ -subunit of the cell surface adhesion molecule LFA-1, on human chromosome 21 by in situ hybridization. *Ann Hum Genet* 1988;52(2):123-8.
9. Wolach B, Gavrieli R, Wolach O, Stauber T, Abuzaitoun O, Kuperman A, *et al.* Leucocyte adhesion deficiency—A multicentre national experience. *Eur J Clin Invest* 2019;49(2):e13047.
10. Etzioni A. Leukocyte-adhesion deficiency, UpToDate 2020 [Available from: <https://www.uptodate.com/contents/leukocyte-adhesion-deficiency>.
11. Sun B, Chen Q, Dong X, Liu D, Hou J, Wang W, *et al.* Report of a Chinese cohort with leukocyte adhesion deficiency-I and four novel mutations. *J Clin Immunol* 2019;39:309-15.
12. Gorjipour H, Chavoshzadeh Z, Fahimzad A, Darougar S. Leukocyte adhesion deficiency type 1: A case series and review of the literature. *EMJ Allergy Immunol* 2019;4(1):95-100.
13. Human genome mutation databank. Human genome mutation data bank. Available at: <https://www.hgmd.cf.ac.uk/docs/login.html>.
14. Tipu HN, Raza R, Jaffar S, Khan A, Anwar MZ, Ahmad W, *et al.*  $\beta$ 2 Integrin Gene (*ITGB2*) mutation spectra in Pakistani families with leukocyte adhesion deficiency type 1 (LAD1). *Immunobiology* 2020;225(3):151938.
15. Tipu HN. Leukocyte adhesion deficiency type I: A rare primary immunodeficiency disorder. *Pediatr Allergy Immunol* 2017;28(3):303-5.
16. Huang C, Lu C, Springer TA. Folding of the conserved domain but not of flanking regions in the integrin  $\beta$ 2 subunit requires association with the  $\alpha$ -subunit. *Proc Natl Acad Sci* 1997;94(7):3156-61.