

ORIGINAL ARTICLE

PROTECTIVE ROLE OF SOYBEAN OIL ON LETROZOLE INDUCED MORPHOLOGICAL CHANGES IN THE TRABECULAR DIAMETER OF LONG BONE: A MOUSE MODEL**Muhammad Haroon, Nabila Momin*, Amber Saba**, Sumaria Javed***, Aisha Sadaf[†], Ulfat Sultana^{††}****Histopathologist, Sifwat Ghayoor Hospital, *Department of Anatomy, Rehman Medical College, **Peshawar Medical College, Peshawar, ***Ayub Medical College, Abbottabad, [†]KMU Institute of Dental Sciences, Kohat, ^{††}Department of Pharmacology, Muhammad College of Medicine, Peshawar, Pakistan**

Background: Letrozole, a commonly prescribed neoadjuvant chemotherapeutic drug in hormone receptor-positive breast cancer females, causes osteoporosis along with several other debilitating effects. Objective of this study was to evaluate the protective role of soybean oil against letrozole-induced histo-morphological changes in femur of mice. **Methods:** This laboratory based experimental study was carried out in animal house at Pakistan Council of Scientific and Industrial Research Centre (PCSIR) Peshawar and Khyber Medical University (KMU). Sixty female albino mice were divided into control (group-A) and experimental groups (B and C respectively). The experimental group B was given Letrozole drug at a dose of 1 mg/Kg/day for 28 days, and Experimental group C was given both Letrozole drug at a dose of 1 mg/Kg/day and 1 ml 10% Soybean oil. The mice were weighed. The animals were sacrificed and femurs were dissected and processed to find out changes in its gross morphology, weight, and trabecular diameter. Trabecular diameter was measured microscopically by using ocular graticule and stage micrometer. Data were analyzed using SPSS-22. Mean and standard deviation were calculated for weight of mice, weight of femur and trabecular diameter. Independent sample *t*-test was applied to compare the continuous variable among two groups. **Results:** The weight of mice, weight of femur and trabecular diameter of femur in mice of Experimental group-C (Soy bean oil) was greater than Experimental group-B (Letrozole) but lesser than control group-A. **Conclusion:** Soybean oil has protective role against letrozole induces bone loss in female albino mice.

Keywords: Letrozole, Soy bean oil, Osteoporosis, Femur, Cancer, Pakistan

Pak J Physiol 2024;20(2):46–9, DOI: <https://doi.org/10.69656/pjp.v20i2.1647>

INTRODUCTION

Cancer is the abnormal growth of cells. The cells may spread from its primary site directly or may spread through lymphatic system to region wise lymph nodes or through blood to various sites where they further grow by process called metastasis.¹ Breast cancer is a heterogeneous disease, diagnosed among women in world over.^{2,3} More than 250,000 breast cancers are diagnosed in the United States every year.⁴ Pakistan is one of the Asian countries having high prevalence of breast cancer.⁵ Oestrogen receptor-positive (ER+) breast cancer is the most common breast cancer subtype.⁶ The risk of having breast cancer is present throughout life. In order to reduce the breast cancer risk the community must be counselled about lactation and increase level of folate in diet. Oestrogen receptor modulators reduces the incidence of breast cancer.⁷

Breast cancer treatment depends upon metastasis to lymph nodes (staging), lymphatic and vascular spread, histological grading, status of hormone receptor, postmenopausal status and age.⁸ There are different methods to manage breast cancer which are as follows: surgery, chemotherapy, hormone/endocrine therapy and radiotherapy.⁹ Chemotherapy and endocrine

therapy reduces recurrence and mortality associated with breast cancer.⁸ Aromatase inhibitors like letrozole should be administered in all postmenopausal women who are having hormone receptor positive breast cancer. Treatment with Letrozole reduces the risk of contralateral breast cancer and also improves the survival rates in patients.⁸ There are various side-effects of Letrozole. Mainly it causes deficiency of oestrogen by aromatase inhibition. Other side-effects include osteoporosis, hot flashes, nausea, fatigue, loss of hair and vaginal bleeding.¹⁰ These side-effects are more common in patients who are treated for breast cancer with Letrozole.¹¹ Letrozole causes about 90% decrease in serum oestrogen level. Letrozole affects the balance between bone reabsorption and bone formation.¹²

Oestrogen inhibits the resorption of bone and stimulates the bone formation. When oestrogen level is reduced after menopause, the resorption of bone predominates and loss of bone continuous. The low level of serum oestradiol reduces the bone mineral density and cause more chance of fracture.¹³ Soy bean oil is derived from plants and comes under class of isoflavones.¹⁴ Isoflavones are plants that belong to class phytoestrogen and are used for cancer therapy,

osteoporosis and cardiovascular disease.¹⁵ When the soy bean oil is ingested, intestinal glucosidases hydrolyzes it and releases glycitein, daidzein, aglycones and ganistein. This is absorbed and metabolized to p-ethyl phenol and equol.¹⁶ The foods produced from soybean are being consumed in Asian countries from centuries and their intake is increased since last decade. Soybean oil is composed of 40% of protein. It has effects on bone as it decreases bone loss, i.e., osteoporosis by decreasing urinary deoxypyridinoline (bone resorbing marker) and by increasing serum alkaline phosphatase (bone forming marker).¹⁷ Cooking oil is used on daily basis so we may replace soy bean oil instead of sunflower, canola oil or olive oil to reduce frequency of bone loss. The aim of this study was to evaluate the protective role of soybean oil against letrozole-induced histo-morphological changes in femur of mice.

MATERIAL AND METHODS

A laboratory based experimental study was designed which included 60 female healthy albino mice. The sample size was calculated through the one-way ANOVA formula for animal studies. The study was approved by the Advanced Study and Research Board (ASRB) (DIR/KMU-AS&RB/TS/000719) and Ethical Board of KGMC (3301/PGMED/KGMC). The study was carried out in Pakistan Council of Scientific and Industrial Research (PCSIR) Animal House, Peshawar, Pakistan from 1st Feb 2022 to 31st Jul 2022. Female albino mice aged 4–6 weeks were included in the study. Exclusion criteria were diseased, inactive, and unhealthy mice. The female albino mice were divided into three groups. Group A served as control having 6 mice and were fed on standard food and tap water whereas group B having 27 mice were given 1 mg/Kg of Letrozole and group C having 27 mice were given 1 mg/Kg of Letrozole along with 1 mL 10% soybean oil (Table-1).¹⁸

Animals in groups were colour coded. The temperature of animal house was kept at 20–27 °C and was maintained according to standard guidelines with 12-12 hours day and night cycle.^{19,20} The drug was administered orally using a syringe with a feeding tube. The animals were observed constantly during initial 24 hours regarding vomiting, activity and other behavioural changes. After 28 days, the animals were sacrificed and femur bones were dissected out. The dissected femur was fixed in 10% neutral buffered formalin (NBF) and transported to histopathology laboratory, Khyber Medical University. The bones were decalcified using 5% Nitric acid. After decalcification, femur bone was washed for removal of traces of nitric acid and subjected to automatic tissue processor.²¹ After processing, paraffin embedded blocks were prepared and labelled accordingly. Blocks were cut at 3–5 microns. The cut tissue was put in water

bath and then was put on glass slide and stained with Haematoxylin and Eosin stain. Prepared slides were examined under microscope. Trabecular diameter was measured using ocular graticule and stage micrometer.

Data were analysed using SPSS-22. Mean and standard deviation were calculated for weight of mice, weight of femur and trabecular diameter. Independent sample *t*-test was applied to compare the continuous variable among two groups, and $p \leq 0.05$ was considered as statistically significant.

Table-1: Number of mice and drug dose in groups

Groups	No.	Daily Dose
Group A (Control Group)	6	Standard Food and Tap Water
Group B (Letrozole Only)	27	Letrozole (1 mg/Kg/day)
Group C (Letrozole+Soy bean Oil)	27	Letrozole (1 mg/Kg/day) +1 mL Soy bean oil

RESULTS

No significant differences in the mean weight of mice were observed before and after the experiment. A significant weight loss was seen in Group B treated with Letrozole as compared to Group A treated with standard food and water, and Group C treated with Letrozole and soy bean oil (Table-2).

Femur bone of all the three groups was dissected, weight of femur was noted, and gross changes like colour and texture were observed (Table-3). The overall mean of weight of femur bone of all the groups was 0.69±0.073 g with group A having mean higher than group B and C, i.e., 0.44±0.087 of group B which is less than mean of group C, i.e., 0.91±0.04. A significant difference in the weight of femur bone between the groups was observed.

The mean trabecular diameter of all groups is shown in Table-4. There was a highly significant difference between the three groups (ANOVA).

The H&E stain photomicrographs are shown in Figure-1.

Table-2: Changes in Mean body Weight (n=60)

Group	Initial Wt (g)	Final Wt (g)	ΔWt (g)	<i>p</i>
Group A	30.33±0.44	30.12±1.45	0.21±1.01	>0.05
Group B	31.92±3.28	17.66±1.85	14.26±1.43	<0.05
Group C	31.07±5.11	22±1.68	9.07±3.43	<0.05

Table-3: Gross features of femur

Gross features	Group A Control	Group B Letrozole	Group C Letrozole+Soy bean Oil
Colour	White, Shining and Glistening	Dull, Dark Brown in colour	Dull, Light Grey in colour
Texture	Smooth	Rough	Slight Rough

Table-4: Comparison of mean diameter of trabecular bone Within the Groups (n=60)

Mean Trabecular Diameters (µm) (Mean±SD)			<i>p</i>
Group A	Group B	Group C	
423.33±25.820	120.37±21.210	234.81±27.50	<0.001

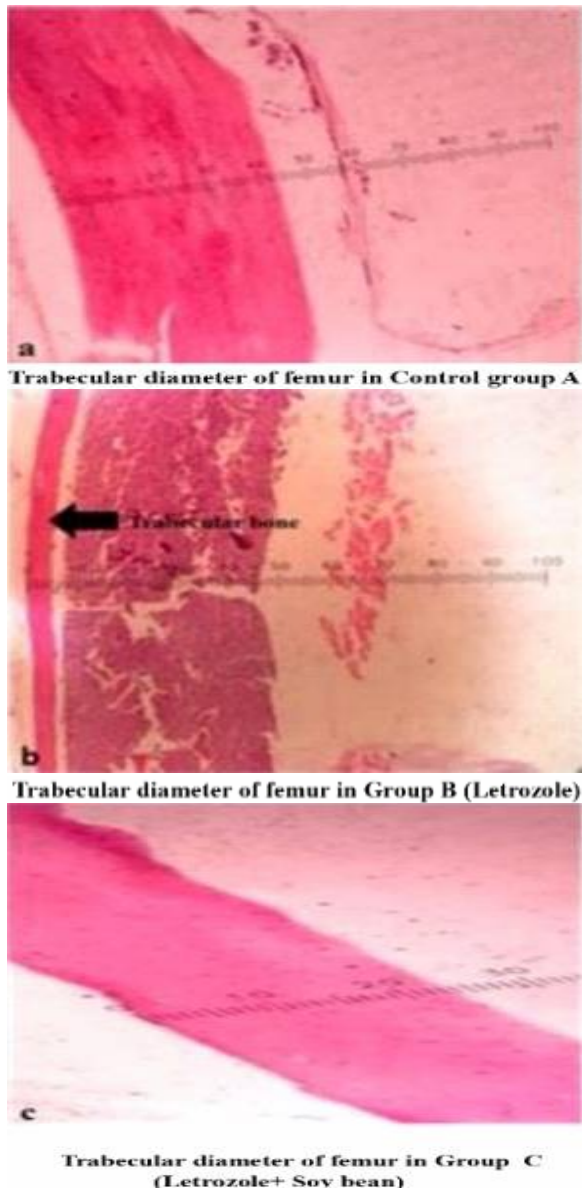


Figure-1: Decalcified section of Femur showing measurement of trabecular bone. H&E stain ($\times 10$)

DISCUSSION

The primary aim of this study was to observe the efficacy of soy bean oil on letrozole induced histomorphological changes in femur bone. This study shed light on the significant decrease in weight of mice and femur bone in letrozole treated group and osteoprotective effects of soy bean oil.

While Letrozole has been shown to be quite beneficial in the treatment of breast cancer, patients' long-term bone health has been adversely affected by this chemotherapeutic drug. The significance of the relationship between steroid sex hormones and bone growth has been widely acknowledged over the last ten years. Letrozole competitively binds to the heme of

cytochrome P450, also known as CYP450 (Aromatase) to suppress the activity of the aromatase enzyme. Long-term aromatase suppression caused a decrease in femur mass, a wavelike arrangement of bone and lamellae, and an altered structure of collagen in compact bone. According to a study conducted on aromatase inhibitor associated bone and musculoskeletal effects revealed that aromatase inhibitors causes weight loss, bone pain, osteopenia, and osteoporosis as well as increase risk of fractures.²² In current study, the amount of damage was observed by gross variables like weight of mice and femur bone, colour and texture of femur bone.

Microscopic quantitative variable like trabecular diameter have been noted by past workers. It was compared with the results of control group as with soy bean oil treated group. Our study showed a significant decrease in weight of mice and femur bone in Letrozole treated group. In past, a study conducted on aromatase inhibitor associated bone and musculoskeletal effects revealed that aromatase inhibitors causes weight loss, bone pain, osteopenia, and osteoporosis as well as increase risk of fractures. Letrozole drug alone given orally caused oestrogen deficiency and significant osteoporosis in femur bone. In one study, 47 fragments of osteoporotic patient bone were collected. Twenty-seven patients aged 60–70 years, femoral head were collected and from twenty patients aged 60–70 years vertebral body were collected. These H and E prepared bone slides were examined under optical microscope showing marked thinness in trabecular bone.²³ In our study Letrozole treated mice showed significantly thin trabecular diameter as compared to control group A. On the other hand Letrozole along with soy bean oil showed mild thinning of trabecular bone which relates to the study conducted by Pilutin *et al*²⁴.

A study conducted in USA (Soy and health update) revealed that food containing soy products promotes health of the bones and prevents bone loss as it contains isoflavones. That study also revealed that women taking soy bean products in their diet reduces osteoporosis and bone fracture risk by one third.²⁵ We observed that Letrozole causes oestrogen deficiency which leads to reduction in weight of mice and femur, increase number of osteoclast cells and decrease trabecular bone diameter. Health professionals may consider soy bean oil in daily diet as it is the best way by which bone loss can be prevented.

The main limitation of our study was that our sample size was small so the results showed higher standard deviation. Increasing size of the sample to ensure reliability and higher validity of results may be used for further conclusive evidence and use of soy bean oil for benefits of health especially for bones.

CONCLUSION

Combination of Letrozole with soy bean oil containing isoflavones have osteoprotective effects showing greater weight, fewer number of osteoclast cells and greater trabecular bone diameter than Letrozole group.

REFERENCES

1. Sudhakar A. History of cancer, ancient and modern treatment methods. *J Cancer Sci Ther* 2009;1(2):1-4.
2. Li C, Uribe D, Daling J. Clinical characteristics of different histologic types of breast cancer. *Br J Cancer* 2005;93(9):1046-52.
3. Ferlay J, Héry C, Autier P, Sankaranarayanan R. Global burden of breast cancer. In: Li C, (Ed). *Breast Cancer Epidemiology*: Springer; 2010. p. 1-19.
4. Waks AG, Winer EP. Breast cancer treatment: A review. *JAMA* 2019;321(3):288-300.
5. Khan NH, Duan SF, Wu DD, Ji XY. Better reporting and awareness campaigns needed for breast cancer in Pakistani women. *Cancer Mang Res* 2021;13:2125-29.
6. Hefli MM, Hu R, Knoblauch NW, Collins LC, Haibe-Kains B, Tamimi RM, *et al.* Estrogen receptor negative/progesterone receptor positive breast cancer is not a reproducible subtype. *Breast Cancer Res* 2013;15(4):R68.
7. Colditz GA. Epidemiology and prevention of breast cancer. *Cancer Epidemiol Biomarkers Prev* 2005;14(4):768-72.
8. Maughan KL, Lutterbie MA, Ham PS. Treatment of breast cancer. *Am Fam Physician* 2010;81(11):1339-46.
9. Sun YS, Zhao Z, Yang ZN, Xu F, Lu HJ, Zhu ZY, *et al.* Risk factors and preventions of breast cancer. *Int J Biol Sci* 2017;13:1387-97.
10. Amer SA, Smith J, Mahran A, Fox P, Fakis A. Double-blind randomized controlled trial of letrozole versus clomiphene citrate in subfertile women with polycystic ovarian syndrome. *Hum Reprod* 2017;32(8):1631-8.
11. Requena A, Herrero J, Landeras J, Navarro E, Neyro JL, Salvador C, *et al.* Use of letrozole in assisted reproduction: a systematic review and meta-analysis. *Hum Reprod Update* 2008;14:571-82.
12. Zaman K, Thürlimann B, Huober J, Schönenberger A, Pagani O, Lüthi J, *et al.* Bone mineral density in breast cancer patients treated with adjuvant letrozole, tamoxifen, or sequences of letrozole and tamoxifen in the BIG 1-98 study (SAKK 21/07). *Ann Oncol* 2011;23(6):1474-81.
13. Yonden Z, Aydin M, Alcin E, Kelestemur MH, Kutlu S, Yilmaz B. Effects of letrozole on bone biomarkers and femur fracture in female rats. *J Physiol Biochem* 2009;65(3):267-75.
14. Barrett JR. The science of soy: what do we really know? *Environ Health Perspect* 2006;114(6):A352-8.
15. Messina M. Soy and health update: evaluation of the clinical and epidemiologic literature. *Nutrients* 2016;8(12):754.
16. Setchell KD, Cassidy A. Dietary isoflavones: biological effects and relevance to human health. *J Nutr* 1999;129(3):758S-767S.
17. Xiao CW. Health effects of soy protein and isoflavones in humans. *J Nutr* 2008;138(6):1244S-1249S.
18. Anwar N, Hamid S, Butt SA. Effect of *Nigella sativa* on number of cystic follicles in letrozole induced polycystic ovaries in mice: *Nigella Sativa & Polycystic Ovaries in Mice*. *Pak Armed Forces Med J* 2016;66(3):310-13.
19. Clark JD, Gebhart GF, Gonder JC, Keeling ME, Kohn DF. The 1996 guide for the care and use of laboratory animals. *ILAR J* 1997;38(1):41-8.
20. Guide for the care and use of laboratory animals. Washington, DC: Institute of Laboratory Animal Resources Commission on Life Sciences, National Research Council, National Academy Press, 1985.
21. Kalam A, Talegaonkar S, Vohora D. Effect of aromatase inhibitors on bone turnover markers in vinyl cyclohexene diepoxide treated ovotoxic female mice. *Preced Br Pharmacol Soc* 2016.
22. Rachner TD, Göbel A, Jaschke NP, Hofbauer LC. Challenges in preventing bone loss induced by aromatase inhibitors. *J Clin Endocrinol Metab* 2020;105(10):3122-33.
23. Marcu F, Bogdan F, Mutiu G, Lazar L. The histopathological study of osteoporosis. *Rom J Morphol Embryol* 2011;52(1 Suppl):321-5.
24. Pilutin A, Misiakiewicz-Has K, Kolasa-Wołosiuk A, Trybek G, Urban F, Marchlewicz M, *et al.* Morphology and serum and bone tissue calcium and magnesium concentrations in the bones of male rats chronically treated with letrozole, a nonsteroidal cytochrome P450 aromatase inhibitor. *Connect Tissue Res* 2021;62(4):454-63.
25. Gaillard S, Stearns V. Aromatase inhibitor-associated bone and musculoskeletal effects: new evidence defining etiology and strategies for management. *Breast Cancer Res* 2011;13(2):205.

Address for Correspondence:

Dr Nabila Momin, Assistant Professor, Department of Anatomy, Rehman Medical College, Peshawar, Pakistan.

Cell: +92-333-6289898

Email: nblmnm@yahoo.com, nabila.momin@rmi.edu.pk

Received: 1 Mar 2024

Reviewed: 18 Mar 2024

Accepted: 3 Apr 2024

Contribution of Authors:

MH: Principal author and Manuscript writer

NM: Laboratory work and histopathological analysis

AS: Laboratory work and animal handling

SJ: Histomorphological analysis

AS: Manuscript editing and Data compilation

US: Statistical Analysis

Conflict of Interest: The authors do not have any conflict of interest.

Funding: None